



**LUMED  
HOSPITAL**

"KALUSUGANG KALIDAD NA ABOT KAYA"

**LA UNION MEDICAL DIAGNOSTIC CENTER & HOSPITAL, INC.**

LUMED Bldg., Ancheta cor Bucaneg St., Catbangen San Fernando City, La Union  
Tel.: +6372 - 610 - 1938, launionmed@gmail.com

**Clinical Laboratory**

Name : <u>ESTIOCO, MAUREEN MAGCIANO</u>	Examination No. : <u>LAB0440067</u>	Patient No. : <u>2100132786</u>
Req. Physician : <u>WALK-IN /OUT-PATIENT</u>	Charge Slip No. : <u>LAB00416824</u>	Case No. : <u>2400030818B</u>
Age : <u>36</u> Sex : <u>FEMALE</u> Room No. : <u>OPD</u>	HMO / Comp. :	Performed : <u>09/29/2024 12:00 AM</u>

**HEMATOLOGY**

TEST	RESULT	REFERENCE
<b>CBC</b>		
WBC	<b>13.69</b>	5.0 - 11.0 x 10 <sup>9</sup> /L
Hemoglobin	<b>133</b>	120 - 160 g/L
Hematocrit	<b>0.40</b>	0.37 - 0.47
RBC	<b>4.44</b>	3.5 - 5.5 x10 <sup>12</sup> /L
<b>DIFFERENTIAL COUNT</b>		
Segmenters	<b>0.57</b>	.50 - .70
Lymphocytes	<b>0.35</b>	.20 - .40
Eosinophils	<b>0.02</b>	0 - .05
Monocytes	<b>0.06</b>	.03 - .08

  
**MACQUELINE R. RETUERNE, RMT PRC 0119705**  
 Medical Technologist

  
**JIMMY S. ROSALES M.D. DPSP PRC0125326**  
 Pathologist

"Health care with sincerity and honesty"

ENCODED & PRINTED BY : HANNAH LUISA JOY PERALTA-09/29/2024 07:33 AM

THIS REPORT IS GENERATED ON HIMS 9.0 FOR LA UNION MEDICAL DIAGNOSTIC CENTER & HOSPITAL, INC. BY THE NEW COMLOGIK BUSINESS SYSTEMS, INC.



**LUMED  
HOSPITAL**

"KALUSUGANG KALIDAD NA ABOT KAYA"

**LA UNION MEDICAL DIAGNOSTIC CENTER & HOSPITAL, INC.**

LUMED Bldg., Ancheta cor Bucaneg St., Catbangen San Fernando City, La Union

Tel.: +6372 - 610 - 1938, launionmed@gmail.com

**Clinical Laboratory**

Name : ESTIOCO, MAUREEN MAGCIANO Examination No. : LAB0440065 Patient No. : 2100132786  
 Req. Physician : WALK-IN /OUT-PATIENT Charge Slip No. : LAB00416824 Case No. : 2400030818B  
 Age : 36 Sex : FEMALE Room No. : OPD HMO / Comp. : \_\_\_\_\_ Performed : 09/29/2024 12:00 AM

**URINE ANALYSIS REPORT**

TEST	RESULT	REFERENCE
<b>PHYSICAL</b>		
Color	<b>YELLOW</b>	
Character	<b>SLIGHTLY TURBID</b>	
Reaction	<b>ACIDIC pH 6.0</b>	
Specific Gravity	<b>1.025</b>	
<b>MICROSCOPIC</b>		
White Blood Cells	<b>0-2/HPF</b>	
Red Blood Cells	<b>0-2/HPF</b>	
Amorphous Urates	<b>FEW</b>	
<b>EPITHELIAL CELLS</b>		
Squamous Cells	<b>FEW</b>	
Mucus Threads	<b>MODERATE</b>	
<b>CHEMICAL</b>		

KAREN RACHELLE C. QUIBIN, RMT PRC 0097925  
 Medical Technologist

JIMMY S. ROSALES M.D.DPSP PRC0125326  
 Pathologist

"Health care with sincerity and honesty"

ENCODED & PRINTED BY : HANNAH LUISA JOY PERALTA-09/29/2024 07:32 AM

THIS REPORT IS GENERATED ON HIMS 9.0 FOR LA UNION MEDICAL DIAGNOSTIC CENTER & HOSPITAL, INC. BY THE NEW COMLOGIK BUSINESS SYSTEMS, INC.



**LUMED  
HOSPITAL**

"KALUSUGANG KALIDAD NA ABOT KAYA"

**LA UNION MEDICAL DIAGNOSTIC CENTER & HOSPITAL, INC.**

LUMED Bldg., Ancheta cor Bucaneg St., Catbangan San Fernando City, La Union

Tel.: +6372 - 610 - 1938, launionmed@gmail.com

**Clinical Laboratory**

Name : <u>ESTIOCO, MAUREEN MAGCIANO</u>	Examination No. : <u>LAB0440065</u>	Patient No. : <u>2100132786</u>
Req. Physician : <u>WALK-IN /OUT-PATIENT</u>	Charge Slip No. : <u>LAB00416824</u>	Case No. : <u>2400030818B</u>
Age : <u>36</u> Sex : <u>FEMALE</u> Room No. : <u>OPD</u>	HMO / Comp. : _____	Performed : <u>09/29/2024 12:00 AM</u>

Protein	<b>NEGATIVE</b>	
Sugar	<b>NEGATIVE</b>	

  
**KAREN RACHELLE C. QUIBIN, RMT PRC 0097925**  
 Medical Technologist

  
**JIMMY S. ROSALES M.D. DPSP PRC0125326**  
 Pathologist

*"Health care with sincerity and honesty"*

ENCODED & PRINTED BY : HANNAH LUISA JOY PERALTA-09/29/2024 07:32 AM

THIS REPORT IS GENERATED ON HIMS 9.0 FOR LA UNION MEDICAL DIAGNOSTIC CENTER & HOSPITAL, INC. BY THE NEW COMLOGIK BUSINESS SYSTEMS, INC.



"KALUSUGANG KALIDAD NA ABOT KAYA"

**LA UNION MEDICAL DIAGNOSTIC CENTER & HOSPITAL, INC.**  
LUMED Bldg., Ancheta cor Bucaneg St., Catbangan San Fernando City, La Union  
Tel.: +6372 - 610 - 1938, launionmed@gmail.com

### X-RAY REPORT

Name : ESTIOCO, MAUREEN MAGCIANO Age: 36 Sex: FEMALE Date Performed : 09/29/2024

X-ray No. : 501 HMO / Company: TASKUS PH Hospital Case No. : 2400030818B

Address: BILIS, BURGOS

Clinical Diagnosis : M.E

Referring Physician : MADAYAG, Jeanette L., M.D.

TYPE OF EXAMINATION: Chest PA

#### FINDINGS:

No abnormal lung opacities seen.  
The heart is not enlarged.  
The diaphragm is normal in contour.  
Bony thorax is intact.

#### IMPRESSION:

Unremarkable study.

JEWEL JEANNE G. BALCITA, RRT.

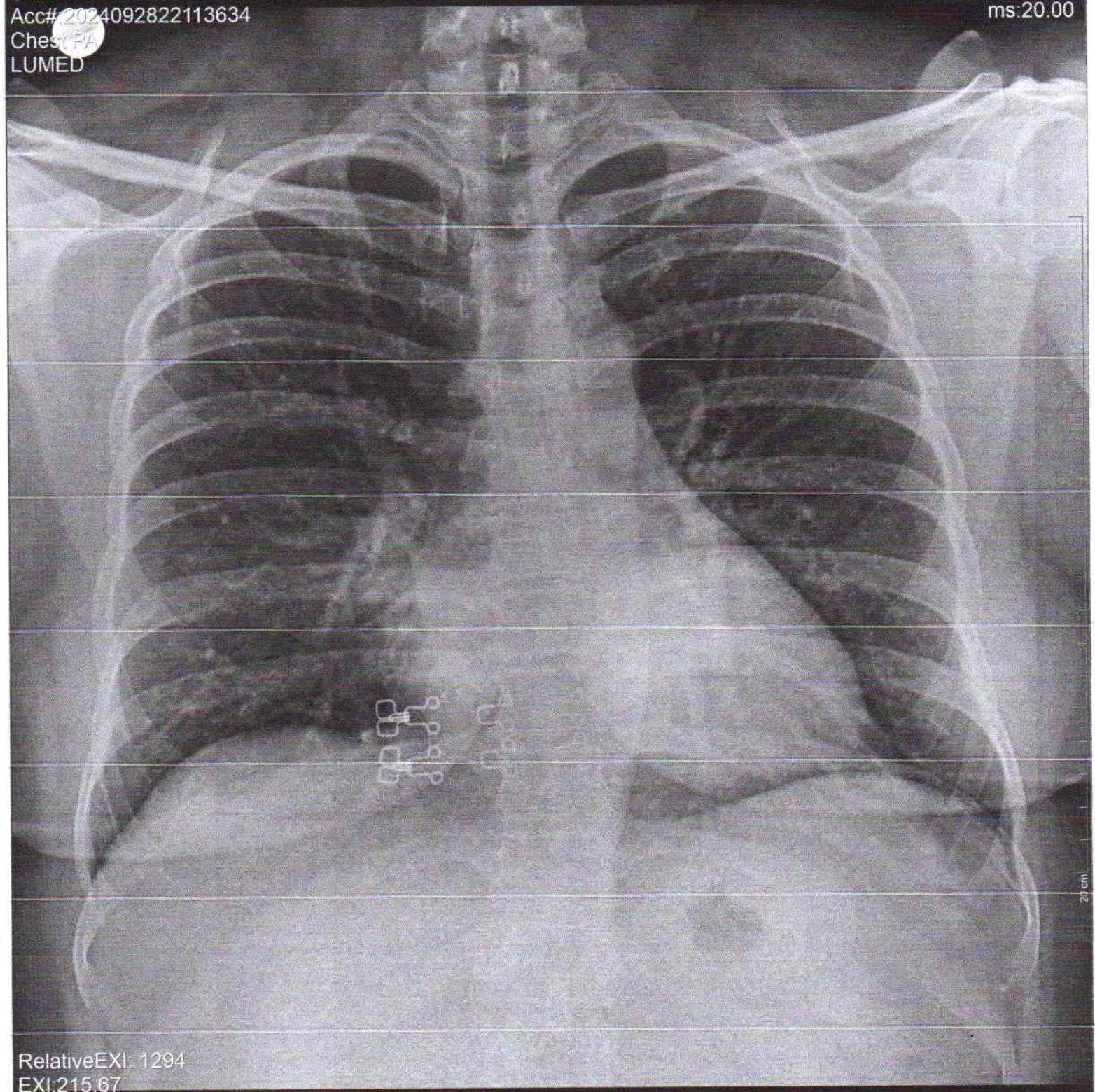
Radiologic Technologist

  
TADAOAN, Carol Grace, M.D., FPCR, FUSP

Radiologist

MAUREEN ESTIOCO  
PID:501  
DOB:28-2024-09  
Age: 000Y  
Sex:  
Acc#:2024092822113634  
Chest PA  
LUMED

Acq:28-2024-09, 04:22:15  
DAP:0.0  
kVp:120.0  
mA: 125  
mAs: 2.50  
ms:20.00



20 cm

RelativeEXI: 1294  
EXI:215.67  
DI:-0.6

Zoom:103% (T)  
WW:4096  
WL:2048

LUMED



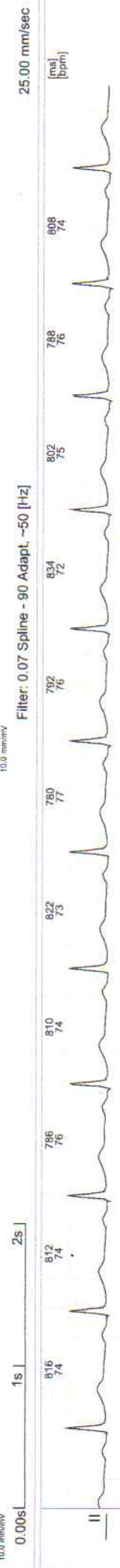
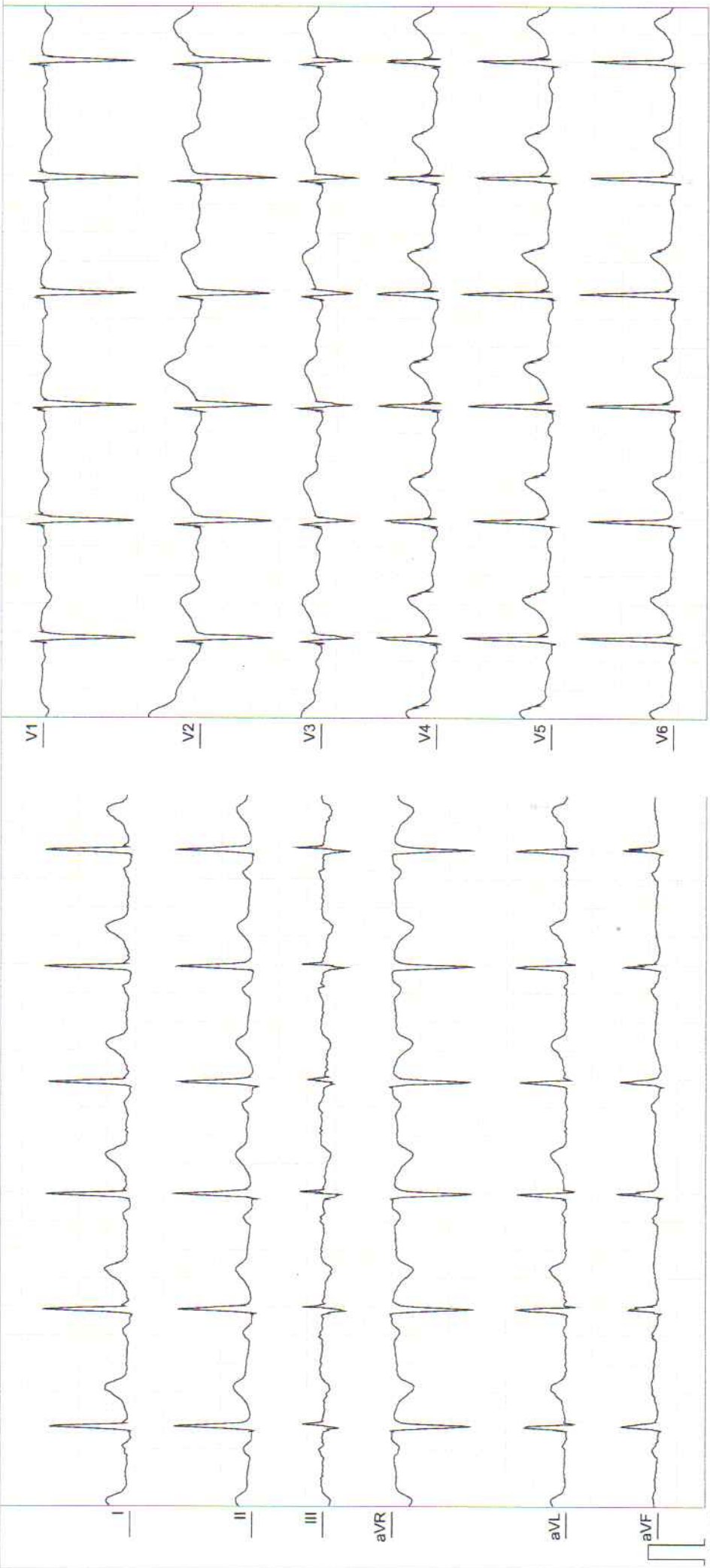
**ESTIACO MAUREEN MAGCIANO**  
 Born: 20/03/1988 (Female 36)  
 Test Date: 28/09/2024 11:31:12 pm  
 Test type: Resting ECG

La Union Medical Diagnostic Center &  
 Hospital, Inc., Catbangen, San Fernando City,  
 La Union

*Passerina  
 D. Coles*

HR	75bpm	P	114ms	P axis	48°
RR	800ms	PQ (PR)	180ms	QRS axis	25°
SpO2		QRS	86ms	T axis	11°
BP		QT	407ms	QTc(Baz)	455ms

*Normal Sinus Rhythm  
 Early Repolarization Pattern*



10.0 mm/mV  
 0.00s | 1s | 2s | 25.00 mm/sec  
 Filter: 0.07 Spline - 90 Adapt. -50 [Hz]  
 816 74 810 74 822 73 786 76 834 72 802 75 788 76 808 74  
 [ms] [bpm]  
 5.0 mm/mV  
 25.00 mm/sec  
 LUMED\_ECG  
 BTL CardioPoint 2.32.38495.0, DIAG: 3.1.1.0; ECG: BTL-08 ECG, SN: 071D0B008589 ECG 10s Page: 1/1



CYTOPATHOLOGY NUMBER:		C24-208				
PATIENT NAME:		ESTIOCO, Maureen				
ATTENDING PHYSICIAN:		Dr. -	AGE	36	Gender	F
REFERRING HOSPITAL:		La Union Medical Diagnostic Center and Hospital, Inc.				
DATE RECEIVED	September 28, 2024	DATE RELEASED	October 2, 2024			
POST-OPERATIVE DIAGNOSIS						

**GYNE CYTOPATHOLOGY REPORT (BETHESDA SYSTEM 2014)**

**SPECIMEN TYPE:** Conventional smear

**SPECIMEN ADEQUACY**

- Satisfactory for evaluation  
 Unsatisfactory for evaluation

**GENERAL CATEGORIZATION (see interpretation)**

- Negative for intraepithelial lesion or malignancy  
 Epithelial cell abnormality  
 Others:

**INTERPRETATION/RESULT**

**NEGATIVE FOR INTRAEPITHELIAL LESION OR MALIGNANCY**

**OTHER NON-NEOPLASTIC FINDINGS**

- Non-neoplastic cellular variations  
 Reactive cellular changes consistent with:  
 Inflammation (includes typical repair)  
 Radiation  
 Intrauterine contraceptive device (IUD)  
 Glandular cells status post hysterectomy

**ORGANISMS:**

- Trichomonas vaginalis  
 Fungal organisms morphologically consistent with Candida spp.  
 Shift in flora suggestive of bacterial vaginosis  
 Bacteria morphologically consistent with Actinomyces spp.  
 Cellular changes consistent with Herpes simplex virus (*multi-nucleated giant cells*)

**OTHERS**

- Endometrial cell (in a postmenopausal woman)

**EPITHELIAL CELL ABNORMALITIES**

**SQUAMOUS CELL**

- Atypical squamous cells  
 of undetermined significance (ASCUS)  
 cannot exclude HSIL (ASC-H)  
 Low grade squamous intraepithelial lesions (LSIL) encompassing HPV changes/mild dysplasia/CIN I  
 High grade squamous intraepithelial lesion (HSIL) encompassing Moderate and severe dysplasia, CIN 2 and CIN 3/CIS  
 With features suggestive of invasion


**GLANDULAR CELL**

- Atypical  
 Endocervical cells       Endometrial cells       Glandular cells  
 Atypical  
 Endocervical cells, favor neoplastic  
 Glandular cells, favor neoplastic  
 Endocervical adenocarcinoma in situ  
 Adenocarcinoma  
 Endocervical       Endometrial  
 Extrauterine       not otherwise specified (NOS)

**COMMENT:**

Mild inflammation  
 CHMI: Superficial cells: 60%      Intermediate cells: 40%      Parabasal cells: 0%  
 Bacterial flora: Bacilli



  
**JIMMY S. ROSALES, M.D., DPSP**  
 Anatomic and Clinical Pathologist