



**LUMED  
HOSPITAL**

"KALUSUGANG KALIDAD NA ABOT KAYA"

**LA UNION MEDICAL DIAGNOSTIC CENTER & HOSPITAL, INC.**

LUMED Bldg., Ancheta cor Bucaneg St., Catbangan San Fernando City, La Union

Tel.: +6372 - 610 - 1938, launionmed@gmail.com

**Clinical Laboratory**

Name : **ROLDAN, ANACORITA ROUS** Examination No. : **LAB0438757** Patient No. : **2300185459**  
 Req. Physician : **WALK-IN /OUT-PATIENT** Charge Slip No. : **LAB00416026** Case No. : **2400031377B**  
 Age : **51** Sex : **FEMALE** Room No.: **OPD** HMO / Comp. : Performed : **09/24/2024 08:00 PM**

**HEMATOLOGY**

TEST	RESULT	REFERENCE
<b>CBC</b>		
WBC	<b>11.25</b>	5.0 - 11.0 x 10 <sup>9</sup> /L
Hemoglobin	<b>150</b>	120 - 160 g/L
Hematocrit	<b>0.45</b>	0.37 - 0.47
RBC	<b>5.0</b>	3.5 - 5.5 x10 <sup>12</sup> /L
<b>DIFFERENTIAL COUNT</b>		
Segmenters	<b>0.56</b>	.50 - .70
Lymphocytes	<b>0.34</b>	.20 - .40
Eosinophils	<b>0.04</b>	0 - .05
Monocytes	<b>0.06</b>	.03 - .08

**ARIANNE M. FERRERIA, RMT/PRC 0104925**  
 Medical Technologist

**JIMMY S. ROSALES M.D.DPSP PRC0125326**  
 Pathologist

"Health care with sincerity and honesty"

ENCODED & PRINTED BY : MACQUELINE R. RETUERNE-09/24/2024 10:33 PM

THIS REPORT IS GENERATED ON HIMS 9.0 FOR LA UNION MEDICAL DIAGNOSTIC CENTER & HOSPITAL, INC. BY THE NEW COMLOGIK BUSINESS SYSTEMS, INC.



**LUMED  
HOSPITAL**

"KALUSUGANG KALIDAD NA ABOT KAYA"

**LA UNION MEDICAL DIAGNOSTIC CENTER & HOSPITAL, INC.**

LUMED Bldg., Ancheta cor Bucaneg St., Catbangan San Fernando City, La Union  
Tel.: +6372 - 610 - 1938, launionmed@gmail.com

**Clinical Laboratory**

Name : ROLDAN, ANACORITA ROUS Examination No. : LAB0438794 Patient No. : 2300185459  
Req. Physician : WALK-IN /OUT-PATIENT Charge Slip No. : LAB00416026 Case No. : 2400031377B  
Age : 51 Sex : FEMALE Room No. : OPD HMO / Comp. : \_\_\_\_\_ Performed : 09/24/2024 08:00 PM

**URINE ANALYSIS REPORT**

TEST	RESULT	REFERENCE
<b>PHYSICAL</b>		
Color	<b>DARK YELLOW</b>	
Character	<b>SLIGHTLY TURBID</b>	
Reaction	<b>ACIDIC PH 6.5</b>	
Specific Gravity	<b>1.025</b>	
<b>MICROSCOPIC</b>		
White Blood Cells	<b>2-4/HPF</b>	
Red Blood Cells	<b>3-5/HPF</b>	
Amorphous Urates	<b>FEW</b>	
<b>EPITHELIAL CELLS</b>		
Squamous Cells	<b>MODERATE</b>	
Mucus Threads	<b>MODERATE</b>	
Bacteria	<b>FEW</b>	

MACQUELINE R. RETUERNE, RMT PRC 0119705  
Medical Technologist

JIMMY S. ROSALES M.D. DPSP PRC0125326  
Pathologist

"Health care with sincerity and honesty"

ENCODED & PRINTED BY : MACQUELINE R. RETUERNE-09/25/2024 12:12 AM

THIS REPORT IS GENERATED ON HIMS 9.0 FOR LA UNION MEDICAL DIAGNOSTIC CENTER & HOSPITAL, INC. BY THE NEW COMLOGIK BUSINESS SYSTEMS, INC.



**LUMED  
HOSPITAL**

"KALUSUGANG KALIDAD NA ABOT KAYA"

**LA UNION MEDICAL DIAGNOSTIC CENTER & HOSPITAL, INC.**

LUMED Bldg., Ancheta cor Bucaneg St., Catbangan San Fernando City, La Union  
Tel.: +6372 - 610 - 1938, launionmed@gmail.com

**Clinical Laboratory**

Name : ROLDAN, ANACORITA ROUS Examination No. : LAB0438794 Patient No. : 2300185459  
 Req. Physician : WALK-IN /OUT-PATIENT Charge Slip No. : LAB00416026 Case No. : 2400031377B  
 Age : 51 Sex : FEMALE Room No. : OPD HMO / Comp. : \_\_\_\_\_ Performed : 09/24/2024 08:00 PM

<b>CHEMICAL</b> Protein Sugar	<b>NEGATIVE NEGATIVE</b>	
-------------------------------------	------------------------------	--

**MACQUELINE R. RETUERNE, RMT PRC 0119705**

Medical Technologist

**JIMMY S. ROSALES M.D. DPSP PRC0125326**

Pathologist

*"Health care with sincerity and honesty"*

ENCODED & PRINTED BY : MACQUELINE R. RETUERNE-09/25/2024 12:12 AM

THIS REPORT IS GENERATED ON HIMS 9.0 FOR LA UNION MEDICAL DIAGNOSTIC CENTER & HOSPITAL, INC. BY THE NEW COMLOGIK BUSINESS SYSTEMS, INC.



**LUMED  
HOSPITAL**

"KALUSUGANG KALIDAD NA ABOT KAYA"

**LA UNION MEDICAL DIAGNOSTIC CENTER & HOSPITAL, INC.**

LUMED Bldg., Ancheta cor Bucaneg St., Catbangan San Fernando City, La Union

Tel.: +6372 - 610 - 1938, launionmed@gmail.com

### X-RAY REPORT

Name : ROLDAN, ANACORITA ROUS Age: 51 Sex: FEMALE Date Performed : 09/25/2024

X-ray No. : 179 HMO / Company: TASKUS PH Hospital Case No. : 2400031377B

Address: OAIG-DAYA, CITY OF CANDON

Clinical Diagnosis : M.E

Referring Physician : MADAYAG, Jeanette L., M.D.

TYPE OF EXAMINATION: Chest PA

#### FINDINGS:

No abnormal lung opacities seen.  
The heart is not enlarged.  
The diaphragm is normal in contour.  
Bony thorax is intact.

#### IMPRESSION:

Unremarkable study.

JEWEL JEANNE G. BALCITA, RRT.

Radiologic Technologist

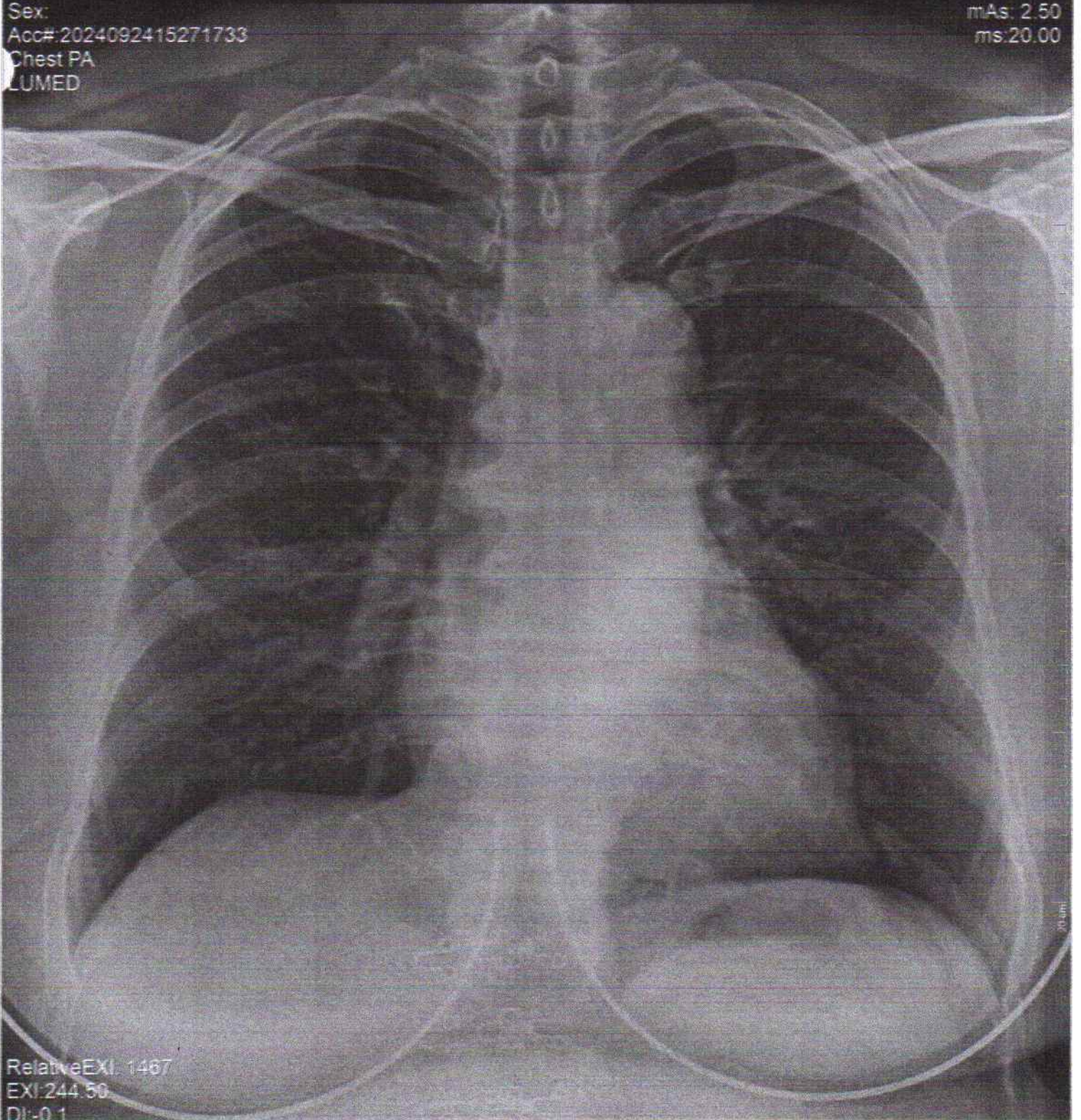
DE GUZMAN, MENCHIE L., RN, M.D., FPCR, FUSP

Radiologist



ANACORITA ROLDAN  
PID:179  
DOB:24-2024-09  
Age: 000Y  
Sex:  
Acc#:2024092415271733  
Chest PA  
LUMED

Acq:24-2024-09, 17:15:31  
DAP:0.0  
kVp:120.0  
mA: 125  
mAs: 2.50  
ms:20.00



RelativeEXI: 1467  
EXI:244.50  
DI:-0.1

Zoom:108% (T)  
WW:4096  
WL:2048

LUMED