



**LUMED  
HOSPITAL**

"KALUSUGANG KALIDAD NA ABOT KAYA"

**A UNION MEDICAL DIAGNOSTIC CENTER & HOSPITAL, INC.**

1ED Bldg., Ancheta cor Bucaneg St., Catbangan San Fernando City, La Union

Tel.: +6372 - 610 - 1938, launionmed@gmail.com

**Clinical Laboratory**

Name : <b>CASIWAN, JUNA NABUS</b>	Examination No. : <u>LAB0441940</u>	Patient No. : <u>2400206162</u>
Req. Physician : <u>IC</u>	Charge Slip No. : <u>LAB00418057</u>	Case No. : <u>2400032810B</u>
Age : <u>45</u> Sex : <u>FEMALE</u> Room No.: <u>OPD</u>	HMO / Comp. :	Performed : <u>10/07/2024 10:25 AM</u>

**HEMATOLOGY**

TEST	RESULT	REFERENCE
<b>CBC</b>		
WBC	<b>7.93</b>	5.0 - 11.0 x 10 <sup>9</sup> /L
Hemoglobin	<b>123</b>	120 - 160 g/L
Hematocrit	<b>0.37</b>	0.37 - 0.47
RBC	<b>4.11</b>	3.5 - 5.5 x 10 <sup>12</sup> /L
<b>DIFFERENTIAL COUNT</b>		
Segmenters	<b>0.70</b>	.50 - .70
Lymphocytes	<b>0.21</b>	.20 - .40
Eosinophils	<b>0.03</b>	0 - .05
Monocytes	<b>0.06</b>	.03 - .08

  
**MARC ANGELO M. CARBONELL, RMT PRC 0104862**  
 Medical Technologist

  
**JIMMY S. ROSALES M.D.DPSP PRC0125326**  
 Pathologist

*"Health care with sincerity and honesty"*

ENCODED & PRINTED BY : JOSEMY MARIANO-10/07/2024 11:18 AM

THIS REPORT IS GENERATED ON HIMS 9.0 FOR LA UNION MEDICAL DIAGNOSTIC CENTER & HOSPITAL, INC. BY THE NEW COMLOGIK BUSINESS SYSTEMS, INC.



**LUMED  
HOSPITAL**

"KALUSUGANG KALIDAD NA ABOT KAYA"

**A UNION MEDICAL DIAGNOSTIC CENTER & HOSPITAL, INC.**

1ED Bldg., Ancheta cor Bucaneg St., Catbangan San Fernando City, La Union


Tel.: +6372 - 610 - 1938, launionmed@gmail.com

**Clinical Laboratory**

Name : <u>CASIWAN, JUNA NABUS</u>	Examination No. : <u>LAB0441939</u>	Patient No. : <u>2400206162</u>
Req. Physician : <u>IC</u>	Charge Slip No. : <u>LAB00418057</u>	Case No. : <u>2400032810B</u>
Age : <u>45</u> Sex : <u>FEMALE</u> Room No.: <u>OPD</u>	HMO / Comp. :	Performed : <u>10/07/2024 11:16 AM</u>

**URINE ANALYSIS REPORT**

TEST	RESULT	REFERENCE
<b>PHYSICAL</b>		
Color	<b>LIGHT YELLOW</b>	
Character	<b>SLIGHTLY TURBID</b>	
Reaction	<b>ACIDIC PH 6.0</b>	
Specific Gravity	<b>1.020</b>	
<b>MICROSCOPIC</b>		
White Blood Cells	<b>2-4/HPF</b>	
Red Blood Cells	<b>0-2/HPF</b>	
Amorphous Urates	<b>FEW</b>	
<b>EPITHELIAL CELLS</b>		
Squamous Cells	<b>FEW</b>	
Mucus Threads	<b>MODERATE</b>	
Bacteria	<b>FEW</b>	

  
**KAREN RACHELLE C. QUIBIN, RMT PRC 0097925**  
 Medical Technologist

  
**JIMMY S. ROSALES, M.D. DPSP PRC0125326**  
 Pathologist

*"Health care with sincerity and honesty"*

ENCODED & PRINTED BY : JOSEMY MARIANO-10/07/2024 11:18 AM

THIS REPORT IS GENERATED ON HIMS 9.0 FOR LA UNION MEDICAL DIAGNOSTIC CENTER & HOSPITAL, INC. BY THE NEW COMLOGIK BUSINESS SYSTEMS, INC.



**LUMED  
HOSPITAL**

"KALUSUGANG KALIDAD NA ABOT KAYA"

**A UNION MEDICAL DIAGNOSTIC CENTER & HOSPITAL, INC.**


11ED Bldg., Ancheta cor Bucaneg St., Catbangan San Fernando City, La Union

Tel.: +6372 - 610 - 1938, launionmed@gmail.com

**Clinical Laboratory**

Name : CASIWAN, JUNA NABUS Examination No. : LAB0441939 Patient No. : 2400206162  
 Req. Physician : IC Charge Slip No. : LAB00418057 Case No. : 2400032810B  
 Age : 45 Sex : FEMALE Room No. : OPD HMO / Comp. : \_\_\_\_\_ Performed : 10/07/2024 11:16 AM

<b>CHEMICAL</b> Protein Sugar	<b>NEGATIVE NEGATIVE</b>	
-------------------------------------	------------------------------	--

  
**KAREN RACHELLE C. QUIBIN, RMT PRC 0097925**  
 Medical Technologist

  
**JIMMY S. ROSALES, M.D. DPSP PRC0125326**  
 Pathologist

*"Health care with sincerity and honesty"*

ENCODED & PRINTED BY : JOSEMY MARIANO-10/07/2024 11:18 AM

THIS REPORT IS GENERATED ON HIMS 9.0 FOR LA UNION MEDICAL DIAGNOSTIC CENTER & HOSPITAL, INC. BY THE NEW COMLOGIK BUSINESS SYSTEMS, INC.

**X-RAY REPORT**

Name : CASIWAN, JUNA NABUS Age: 45 Sex: FEMALE Date Performed : 10/07/2024

X-ray No. : 24-14504 HMO / Company: TASKUS PH Hospital Case No. : 2400032810B

Address: PICO, LA TRINIDAD

Clinical Diagnosis : ME

Referring Physician : N/A

TYPE OF EXAMINATION: Chest PA

FINDINGS:

No abnormal lung opacities seen.  
The heart is not enlarged.  
The diaphragm is normal in contour.  
Bony thorax is intact.

IMPRESSION:

Unremarkable study.

  
MELDA P. OMANHAN, RRT.

Radiologic Technologist

  
DE GUZMAN, MENCHIE L., RN, M.D., FPCR, FUSP

Radiologist

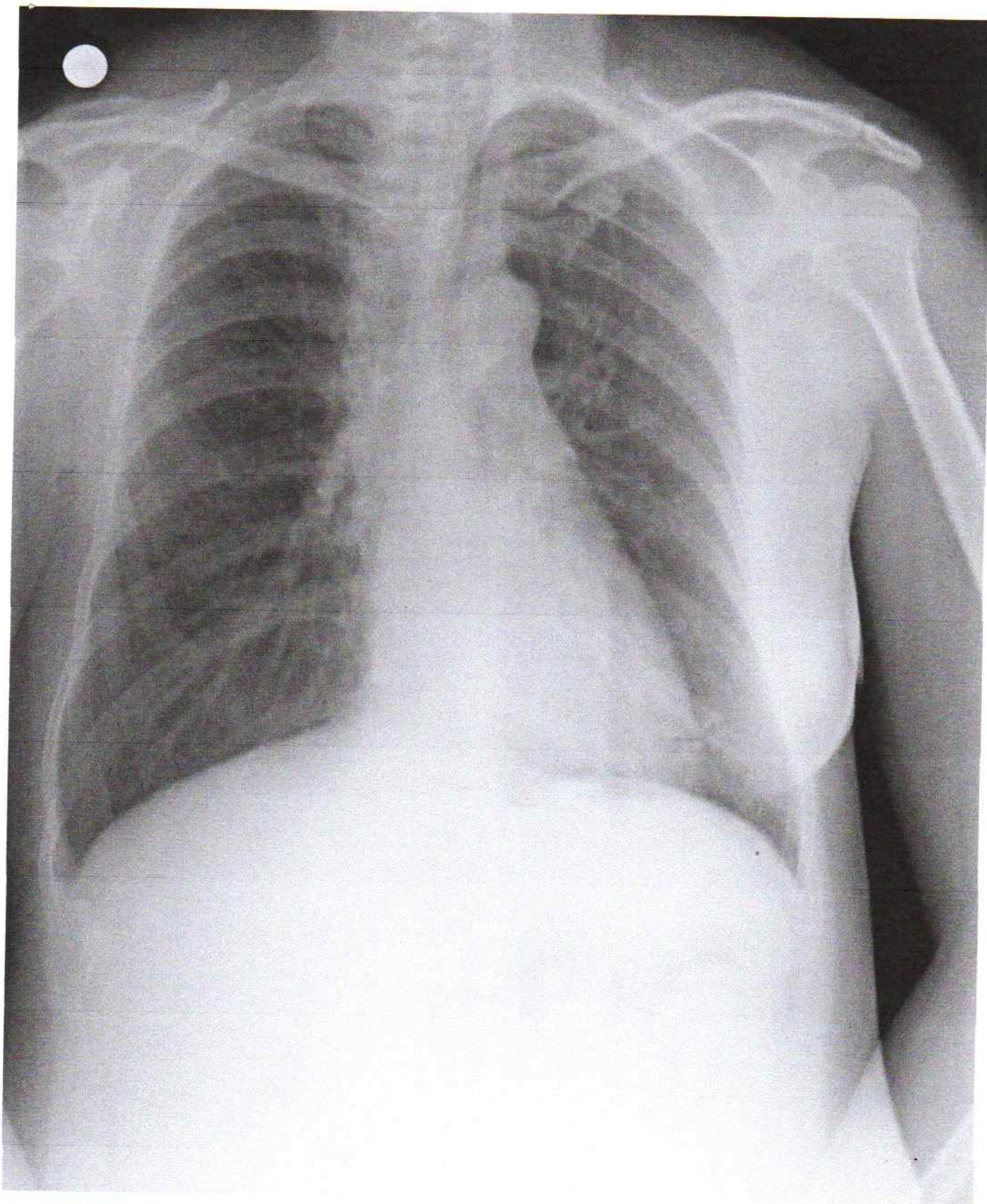


Image date: 10/07/2024 09:16:01

**CASIWAN JUNA NABUS**

Born: 23/06/1979 (Female 45)  
 Test Date: 07/10/2024 9:40:57 am

Test type: Resting ECG

La Union Medical Diagnostic Center &  
 Hospital, Inc., Catbangen, San Fernando  
 City, La Union

TRASK MS

HR	68bpm	P	120ms	P axis	41°
RR	882ms	PQ (PR)	160ms	QRS axis	68°
SpO2		QRS	88ms	T axis	33°
BP		QT	419ms	QTc(Baz)	446ms

*ST segment depression I, II, aVF  
 considered up. well within  
 pub- acceptable clinically*

*AK*  
 Rosella L. Dizon, M.D.  
 Internal Medicine  
 Lic. No. 65264

