



**LUMED  
HOSPITAL**

"KALUSUGANG KALIDAD NA ABOT KAYA"

**A UNION MEDICAL DIAGNOSTIC CENTER & HOSPITAL, INC.**

1ED Bldg., Ancheta cor Bucaneg St., Catbangan San Fernando City, La Union

Tel.: +6372 - 610 - 1938, launionmed@gmail.com

**Clinical Laboratory**

Name : PASTOR, TRISHA TUNGILAB Examination No. : LAB0438774 Patient No. : 2400206159  
 Req. Physician : WALK-IN /OUT-PATIENT Charge Slip No. : LAB00416029 Case No. : 2400031303B  
 Age : 25 Sex : FEMALE Room No.: OPD HMO / Comp. : \_\_\_\_\_ Performed : 09/24/2024 08:00 PM

**HEMATOLOGY**

TEST	RESULT	REFERENCE
<b>CBC</b>		
WBC	<b>6.54</b>	5.0 - 11.0 x 10 <sup>9</sup> /L
Hemoglobin	<b>127</b>	120 - 160 g/L
Hematocrit	<b>0.38</b>	0.37 - 0.47
RBC	<b>4.22</b>	3.5 - 5.5 x10 <sup>12</sup> /L
<b>DIFFERENTIAL COUNT</b>		
Segmenters	<b>0.56</b>	.50 - .70
Lymphocytes	<b>0.35</b>	.20 - .40
Eosinophils	<b>0.04</b>	0 - .05
Monocytes	<b>0.05</b>	.03 - .08

  
**ARIANNE M. FERRERIA, RMT PRC 0104925**  
 Medical Technologist

  
**JIMMY S. ROSALES M.D.DPSP PRC0125326**  
 Pathologist

*"Health care with sincerity and honesty"*

ENCODED & PRINTED BY : ARIANNE M. FERRERIA-09/24/2024 11:07 PM

THIS REPORT IS GENERATED ON HIMS 9.0 FOR LA UNION MEDICAL DIAGNOSTIC CENTER & HOSPITAL, INC. BY THE NEW COMLOGIK BUSINESS SYSTEMS, INC.



**LUMED  
HOSPITAL**

"KALUSUGANG KALIDAD NA ABOT KAYA"

**A UNION MEDICAL DIAGNOSTIC CENTER & HOSPITAL, INC.**

11ED Bldg., Ancheta cor Bucaneg St., Catbangan San Fernando City, La Union

Tel.: +6372 - 610 - 1938, launionmed@gmail.com

**Clinical Laboratory**

Name : **PASTOR, TRISHA TUNGILAB** Examination No. : LAB0438773 Patient No. : 2400206159  
 Req. Physician : WALK-IN /OUT-PATIENT Charge Slip No. : LAB00416029 Case No. : 2400031303B  
 Age : 25 Sex : FEMALE Room No.: OPD HMO / Comp. : \_\_\_\_\_ Performed : 09/24/2024 08:00 PM

**URINE ANALYSIS REPORT**

TEST	RESULT	REFERENCE
<b>PHYSICAL</b>		
Color	<b>DARK YELLOW</b>	
Character	<b>SLIGHTLY TURBID</b>	
Reaction	<b>ACIDIC PH 6.5</b>	
Specific Gravity	<b>1.010</b>	
<b>MICROSCOPIC</b>		
White Blood Cells	<b>8-10/HPF</b>	
Red Blood Cells	<b>3-5/HPF</b>	
Amorphous Urates	<b>FEW</b>	
<b>EPITHELIAL CELLS</b>		
Squamous Cells	<b>MODERATE</b>	
Mucus Threads	<b>MODERATE</b>	
Bacteria	<b>FEW</b>	

**ARIANNE M. FERRERIA, RMT PRC 0104925**

Medical Technologist

**JIMMY S. ROSALES M.D. DPSP PRC0125326**

Pathologist

"Health care with sincerity and honesty"

ENCODED & PRINTED BY : ARIANNE M. FERRERIA-09/24/2024 11:05 PM

THIS REPORT IS GENERATED ON HIMS 9.0 FOR LA UNION MEDICAL DIAGNOSTIC CENTER & HOSPITAL, INC. BY THE NEW COMLOGIK BUSINESS SYSTEMS, INC.



**LUMED  
HOSPITAL**

"KALUSUGANG KALIDAD NA ABOT KAYA"

**A UNION MEDICAL DIAGNOSTIC CENTER & HOSPITAL, INC.**

1ED Bldg., Ancheta cor Bucaneg St., Catbangan San Fernando City, La Union


Tel.: +6372 - 610 - 1938, launionmed@gmail.com

**Clinical Laboratory**

Name : PASTOR, TRISHA TUNGILAB Examination No. : LAB0438773 Patient No. : 2400206159  
 Req. Physician : WALK-IN /OUT-PATIENT Charge Slip No. : LAB00416029 Case No. : 2400031303B  
 Age : 25 Sex : FEMALE Room No.: OPD HMO / Comp. : \_\_\_\_\_ Performed : 09/24/2024 08:00 PM

<b>CHEMICAL</b> Protein Sugar	<b>NEGATIVE NEGATIVE</b>	
-------------------------------------	------------------------------	--

  
**ARIANNE M. FERRERIA, RMT PRC 0104925**  
 Medical Technologist

  
**JIMMY S. ROSALES M.D.DPSP PRC0125326**  
 Pathologist

*"Health care with sincerity and honesty"*

ENCODED & PRINTED BY : ARIANNE M. FERRERIA-09/24/2024 11:05 PM

THIS REPORT IS GENERATED ON HIMS 9.0 FOR LA UNION MEDICAL DIAGNOSTIC CENTER & HOSPITAL, INC. BY THE NEW COMLOGIK BUSINESS SYSTEMS, INC.

**X-RAY REPORT**

Name : PASTOR, TRISHA TUNGILAB Age: 25 Sex: FEMALE Date Performed : 09/25/2024

X-ray No. : 178 HMO / Company: TASKUS PH Hospital Case No. : 2400031303B

Address: POBLACION, LA TRINIDAD

Clinical Diagnosis : M.E

Referring Physician : MADAYAG, Jeanette L., M.D.

TYPE OF EXAMINATION: Chest PA

FINDINGS:

No abnormal lung opacities seen.  
The heart is not enlarged.  
The diaphragm is normal in contour.  
Bony thorax is intact.

IMPRESSION:

Unremarkable study.

  
JEWEL JEANNE G. BALCITA, RRT.

Radiologic Technologist

  
DE GUZMAN, MENCHIE L., RN, M.D., FPCR, FUSP

Radiologist

TRISHA PASTOR

PID: 178

DOB: 24-2024-09

Age: 000Y

Sex:

Acc#: 2024092415241432

Chest PA

LUMED

Acq: 24-2024-09, 26:15:28

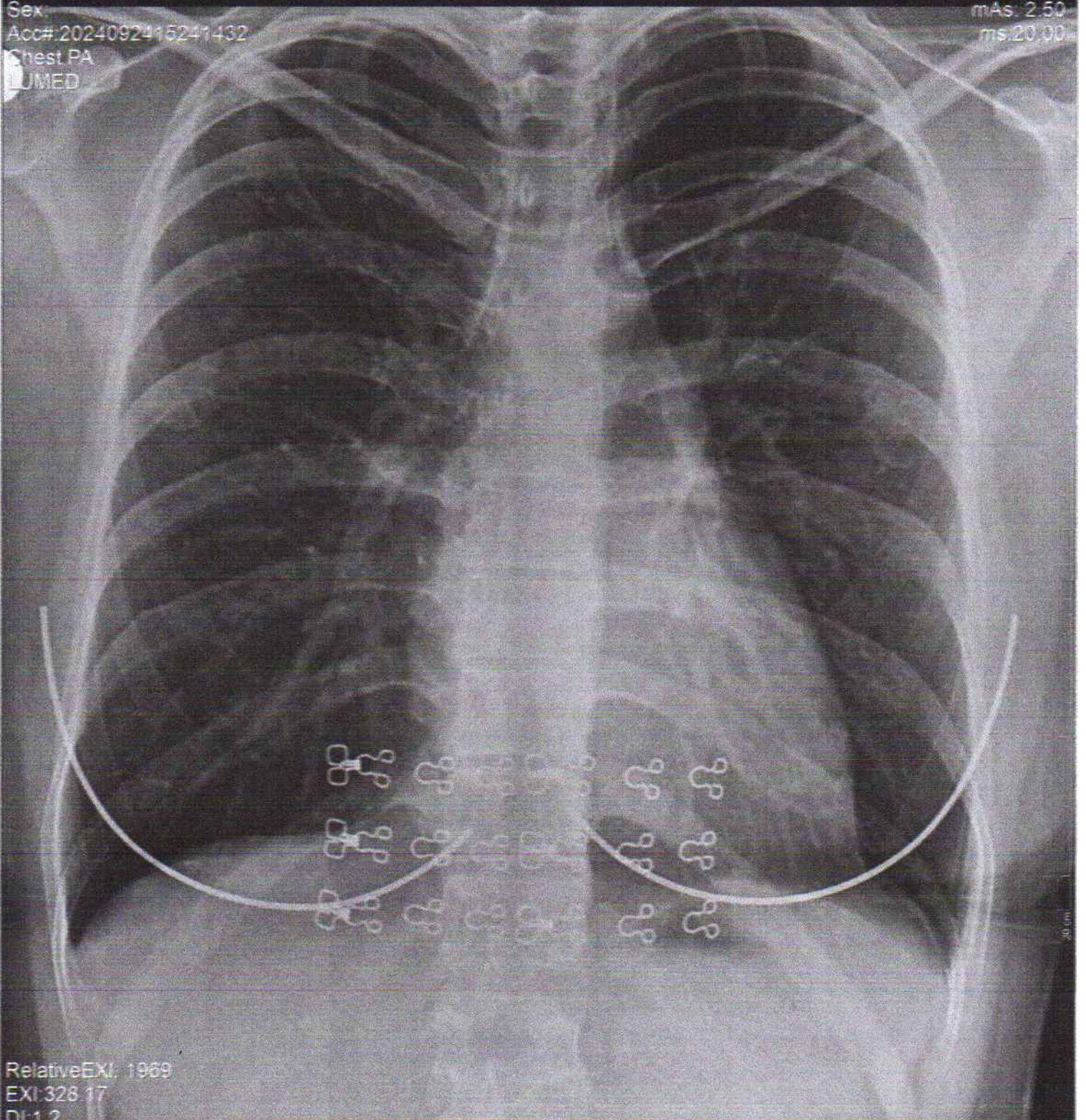
DAP: 0.0

kVp: 120.0

mA: 125

mAs: 2.50

ms: 20.00



RelativeEXI: 1969

EXI: 328.17

DI: 1.2

Zoom: 110% (T)

WW: 4096

WL: 2048

LUMED